

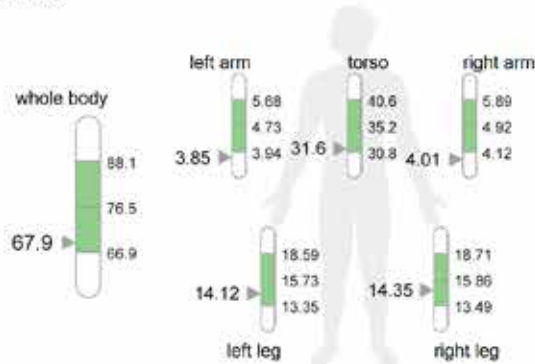


Patient Data

ID: 1264
Name: John Doe
41 Male 05.12.2017 12:35

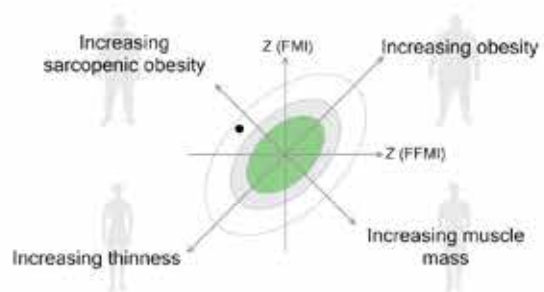
Skeletal Muscle Mass

Skeletal Muscle Mass (SMM):
67.93 lbs



Body Composition Chart

Fat Mass Index (FMI): 8.5 kg/m²
Fat-Free Mass Index (FFMI): 17.8 kg/m²



Fat Mass

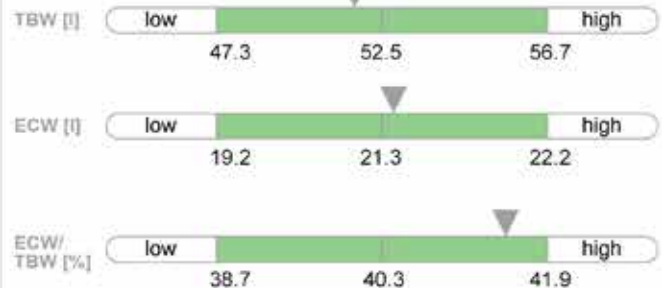Fat Mass (FM): 60.73 lbs (32.3%)*
Fat Mass Index (FMI): 8.5 kg/m²



Water

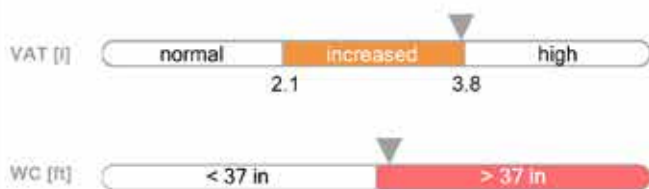
Total Body Water (TBW): 52.0 l (49.5%)*
Extracellular Water (ECW): 21.5 l (20.5%)*

ECW/TBW:
41.3%



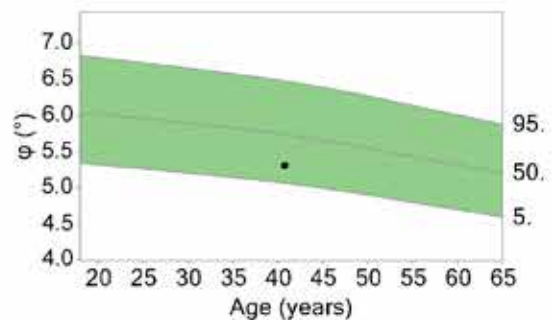
Visceral Adipose Tissue & Waist Circumference

Visceral Adipose Tissue (VAT): 3.7 l
Waist Circumference (WC): 38"



Phase Angle

Phase Angle (φ): 5.3°
Percentile: 12.



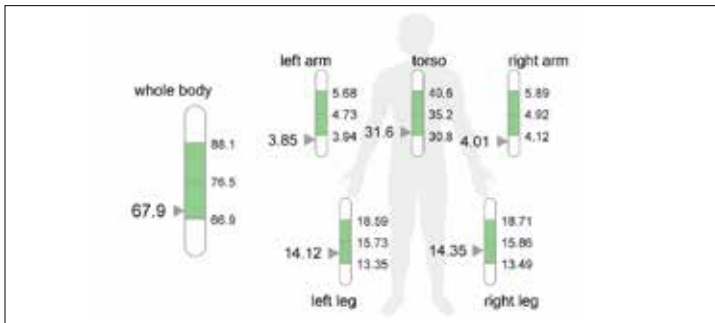
Your seca mBCA measurements – clearly presented and explained.

More than just BMI

Even patients of a normal weight (Body Mass Index of 18.5-24.9 kg/m²) can have excess fat, putting them at higher risks for diseases. Relying on height and weight alone has major shortcomings: false positives with fit patients, false negatives with TOFI (thin on the outside, fat on the inside) patients, and misdiagnosis. In order to see the whole picture and understand what treatment plans best fit your patients, a comprehensive body composition analysis is essential.

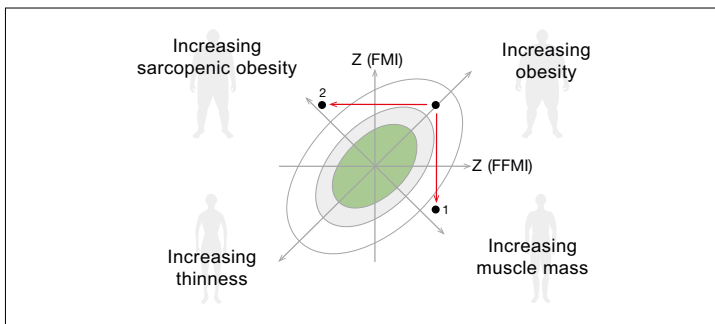
Skeletal Muscle Mass

The visualization of Muscle Mass not only helps you to assess the risk of sarcopenia or its precursors in your patients, it also shows you in detail how your therapy regimen is working in a thorough trend analysis. Whole-body MRI derived bio impedance equations are much more accurate for predicting muscle mass than DXA¹.



Body Composition Chart (BCC)

The BCC plots Fat Mass and Fat Free Mass in one chart. With one glimpse you can get an overview of the individual body composition of your patient. Is your patient “just” obese or is sarcopenic obesity present?

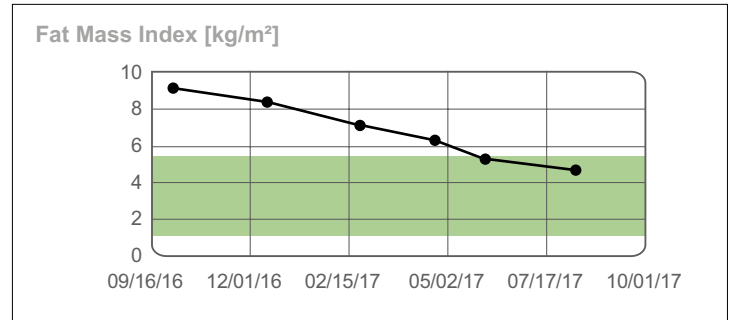


Viewing the trend allows you to qualify weight loss into healthy loss of Fat Mass (vertical, point 1) or into unhealthy loss of Fat Free Mass (horizontal, point 2).

¹Eur J Clin Nutr 2017 Sep; 71(9): 1061-1067; doi: 10.1038/ejcn.2017.27. Epub 2017 Mar 22. Quantification of whole-body and segmental skeletal muscle mass using phase-sensitive 8-electrode medical bioelectrical impedance devices. Bösny-Westphal A, Jensen B, Braun W, Pourhassan M, Gallagher D, Müller MJ.

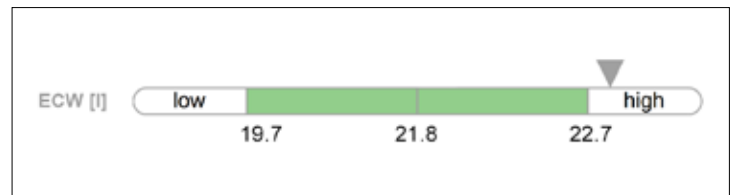
Fat Mass

Granting a more detailed look and quantifying the loss of Fat Mass. Use Body Fat Percentage or Fat Mass Index (FMI), whatever you prefer, and see how your intervention shreds away the excessive fat depots.



Water

Monitoring the hydration status is not only important in weight loss but especially in (B)HRT, where water retention e.g. due to higher aromatase activity can be detected in follow-up measurements.



Visceral Adipose Tissue & Waist Circumference

According to the International Diabetes Foundation, the main diagnosis criterion of metabolic syndrome is central obesity. Abdominal obesity is independently associated with insulin resistance, dyslipidaemia and raised blood pressure. Estimate the cardiometabolic risk with absolute values of the Visceral Adipose Tissue and visualize the effects of your therapy.

Phase angle

A high phase angle shows the good condition of the cells and their functions and is thereby an indicator of a generally good state of health. Inflammation and low muscle mass decrease the phase angle meaningfully.